



An alternate option for the humane euthanasia of marine turtles: Green Turtle Dispatching Harness Project for the Torres Strait Islands

April 2016

Flint, M., and Mills, P.



***An alternate option for the humane euthanasia of
marine turtles:***

**Green Turtle Dispatching Harness Project
for the Torres Strait Islands**

Dr Mark Flint^{1,2} BVSc, BSc(HONS), MAPPLSc, MPhil, PhD

Professor Paul Mills¹ BVSc, PhD, MACVSc, GCED, MPhil (VET ED)

¹Vet-MARTI unit

School of Veterinary Science
The University of Queensland
Gatton, Queensland, 4343.

Email: flintm@ufl.edu

²School of Forest Resources & Conservation

University of Florida
The Florida Aquarium's Center for Conservation
Apollo Beach, Florida, 33572

April 2016

TABLE OF CONTENTS

List of Tables	ii
List of Figures	ii
Executive Summary	1
Acknowledgements	3
Introduction	4
Aim, objectives and milestones	6
The aim of this project was to:	6
The objectives of this project were to:	6
Project Milestones	7
Materials and Methods	8
Device development	8
Carcasses (probe, broom and stone)	9
Anaesthetised live turtles	10
Field captured live turtles	11
Confirmation of method success	11
Community feedback	11
Permitting considerations	12
Results	13
Carcasses (probe, broom and stone)	13
Live turtles (probe only)	14
Histology	15
Community feedback	15
Discussion	16
Conclusion	18
Recommendations	19
References	21

LIST OF TABLES

Table 1:	The project milestones, timeframes and stage of the project summarised as follows..	7
Table 2:	Stage 1 (carcasses) and Stage 2 (live) outcomes for the three methods employed to achieve euthanasia.....	14
Table 3:	Duration from deployment of device to confirmed death of the turtle in live turtles.....	15

LIST OF FIGURES

Figure 1:	Device evolution throughout the project. All conform to the same mechanism of action.	9
Figure 2:	Typical (a) presentation for correct penetration of the device through the skull at the caudal aspect of the frontoparietal scale; (b) longitudinal section showing passage of probe (encircled) with severed spinal cord and ablated midbrain with disruption of the hindbrain; (c) gross appearance of a brain that has successfully had the device deployed where the hind brain is ablated (large circle) and spinal cord (small circle) is severed; and (d) the resultant histology showing separation of the spinal cord (arrows) and the disrupted architecture of the hindbrain.....	13

EXECUTIVE SUMMARY

This project was undertaken following advice from a Steering Committee that included invited members from the Torres Strait Regional Authority, Queensland Department of Environment and Heritage Protection, Great Barrier Reef Marine Park Authority, RSPCA Queensland, James Cook University, DAFF- Animal Welfare unit, AIATSIS, and AFMA. Between July 2012 and December 2015, 27 marine turtles were examined to develop and test a humane euthanasia device for green marine turtles for use in the Torres Strait Islands. This device was then introduced through a series of Community demonstrations on Masig, Badu, Mabuiag, and Moa Islands and provided to Traditional Owner hunters of Masig, Badu and Mabuiag to trial.

These animals included:

- 20 marine turtle carcasses tested and dissected for the brain to be examined grossly and histologically to determine the effectiveness of the proposed device; examined by one of three methods- probe ($n = 11$), broom ($n = 5$) and broomstick ($n = 4$).
- 5 marine turtles independently diagnosed as having a grave prognosis and candidates for euthanasia. These turtles were anaesthetised prior to deploying the device.
- 2 marine turtles caught as part of subsistence hunting in the Torres Straits. These animals were to be euthanased by Traditional methods but the Indigenous hunters permitted the device to be deployed as part of a community demonstration of the developed method and hardware.

Since this time, Traditional hunters have trialled the device on several turtles as part of their traditional hunting practices.

The device concept (a probe to enter the skull dorsocaudally to ablate the hindbrain and sever the spinal cord) remained unchanged throughout the project.

The design of the device evolved with trials and after seeking Community feedback in April 2013 and during demonstrations in March 2015.

The principal of the device was sound and effective to dispatch a marine turtle within the recommendations outlined by American Veterinary Medical Association (AVMA) Guidelines on Euthanasia.

After trialling the device for 6 months, the Traditional Owners of Masig, Badu and Mabuiag provided feedback on their thoughts on the device after 3 years of trialling. In summary- they expressed a willingness to continue to trial the device, but they would prefer modification to the device to assist with (i) single man hunting, (ii) ease of fitting and deployment of the probe for a

range of turtle sizes, and (iii) facilitate restraint of the turtle during fitting and deployment by allowing the turtle to be on its back.

ACKNOWLEDGEMENTS

The authors wish to thank the Torres Strait Regional Authority staff for all of their help, guidance, and organisation throughout this project; the UQ Animal Ethics Committee for constructive feedback for each stage of this project; the Steering Committee formed to advise on this project with experts from the government, indigenous, welfare, and academic sectors, external advisers including Dr. Col Limpus (Department of Environment and Heritage Protection); and histopathological assistance from Dr. Helen Owen (UQ).

All research was performed under Scientific Purposes Permit (through DEHP-WISP11995112), an Animal Ethics Number (through UQ- SVS/342/12/TSRA) and a Human Ethical Clearance Number (through UQ- 2012000895).

INTRODUCTION

Marine turtles are caught and slaughtered for consumption as part of traditional Indigenous community harvest in Australia as well as in almost all countries in which marine turtles can be found.

In early March 2012, a story aired on the ABC's *7:30 Report* that questioned the Traditional hunting practices of turtles and dugongs; as well as the illegal trade of products of these species of conservation concern (<http://www.abc.net.au/7.30/content/2012/s3448943.htm>). The result was a public backlash causing the *Animal Care and Protection Act 2001* to be changed to remove the exemption from animal welfare obligations that existed for Aboriginal people acting according to Aboriginal tradition and Torres Strait Islander people acting according to Islander custom. An offence exemption is now included to ensure that these animals when killed in the exercise of Aboriginal tradition or Island custom are killed in a way that causes *as little pain as is reasonable*.

In response to this change in legislation, the Torres Strait Regional Authority (TSRA), under guidance from the Great Barrier Reef Marine Park Authority (GBRMPA) and Queensland Department of Environment and Heritage Protection (EHP), determined that a humane alternative to current Traditional hunting practices to euthanase marine turtles was warranted to permit hunters to continue Traditional practices within the rules of the legislation.

However, in many Torres Strait Island communities, ethically-acceptable euthanasia solutions (e.g. lethal injection drugs, such as sodium pentobarbitone) and weapons, including firearms and stun guns, are restricted without special licenses and risk harm to those using it or eating meat from animals destroyed this way. Traditional methods of euthanasia vary between communities. In general, the turtle is placed on their back and a sharp blow is delivered to the rostrum or the top of the head by a large stone when the turtle's head is extended clear of the carapace ("stone method") or a palm frond is taken and stripped of leaves to create a sharp probe that is inserted through the nasal cavity ("broom stick method"). To keep with the practicality of these methods, a simple device with minimal moving parts is required to allow for the rapid euthanasia of healthy large green marine turtles caught for consumption as part of traditional owner practices.

The proposed device would need to stabilise the skull and restrict head movement for the direction of a sharp probe through the hindbrain (by 'pithing'- the destruction of the central nervous system) and severing of the spinal cord ensuring death and ablation of sensation. Ablation of the hindbrain, including severing of the spine, will be considered successful in achieving euthanasia by replicating pithing and decapitation in a single function. Pithing and decapitation causing destruction of the brain and spinal cord is recommended by the AVMA Guidelines on Euthanasia (2007, reviewed 2012)

(http://www.aphis.usda.gov/animal_welfare/downloads/reports_out/euthanasia.pdf) as an acceptable combination method for the euthanasia of reptiles.

Although simple in theory, there are several problems which may occur trying to euthanase a reptile with a solid exoskeleton that can weigh anywhere up to 120 kg. Problems to overcome when designing the device are (1) the mobility of a healthy green marine turtle even if placed on its carapace; (2) the elasticity of the skull to percussive insults; (3) reliably positioning the probe to ablate the hindbrain from a dorsal approach (as turtle forebrain insults are seldom fatal); (4) the need for a 'single blow' euthanasia method; (5) Indigenous community restrictions; (6) Indigenous and wider community perception; and (7) the need for a durable device with few moving parts that will not wear out or fail with prolonged exposure to marine elements.

AIM, OBJECTIVES AND MILESTONES

The aim of this project was to:

Establish an alternative option for the humane euthanasing of marine turtles.

The objectives of this project were to:

1. Develop a euthanasia harness device for testing
2. Trial harness in a step-wise manner on carcasses through to live healthy marine turtles
3. Engage the Indigenous Communities in trialling the device and providing feedback to its effectiveness as an alternative option to current practices.
4. Report ongoing and final findings to the TSRA and Project Steering Committee.

Project Milestones

Table 1: The project milestones, timeframes and stage of the project summarised as follows.

Milestone	Itemised tasks	Timeframe	Stage
1. Development of Harness Prototype	Initial proposal of harness for Steering Committee feedback	July 2, 2012	
	Feedback received from Steering Committee	July 10, 2012	
	Modification of harness as required	July 16, 2012	
	Approval from Steering Committee	July 20, 2012	
2. Trial Harness	Engage with GBRMPA & QDERM to trial harness on green turtle carcasses	Aug 10, 2012	
	TSRA staff to discuss with rangers to identify interested TS communities to trial harness	Aug 10, 2012	
	LSMU and rangers to have community meeting seeking support and outlining trial period	Aug 17, 2012	
		Dec 15, 2012	Stage 1- 50 carcasses Trial device on carcasses to assess brain ablation using two probe sizes in adult green turtles
		May 15, 2014	Stage 2- 5 live turtles Using selected probe & device design to assess ability to euthanase on anaesthetised turtles.
		Mar 20, 2015	Stage 3- 20 live turtles Trial final device design in 4 communities with a max of 5 turtles for each community by TSRA/Vet (suggest 1 turtle per community).
		Up to July 20, 2015	Stage 4- Trial final device design in 4 communities with a max of 5 turtles for each community by Community including those used in Stage 3.
3. Community Engagement	Rangers and Consultant to seek feedback from communities regarding effectiveness of harness after a 5 month trial period	July 20, 2015	All to use UQ Human Ethics approval
	If needed, consultant to make modifications	Aug 15, 2015	
4. Outputs including Reports	Finalised version of harness prototype completed	Aug 15, 2015	
	Interim reports due	Mar 30, 2015	
	Final report due	Oct 30, 2015	
5. Ongoing	Consultant held on retainer: Oct 12, 2012 to July 12, 2013 and longer by arrangement	July 12, 2013	

MATERIALS AND METHODS

Device development

There were four device types (Device 1-4) used from the first prototype in July 2012 through to the device left among the Communities at the conclusion of the project between May and November 2015 (Figure 1). Each followed the same principle of penetrating the hindbrain and severing the spinal cord by introduction of a 9 mm diameter 240 mm long probe perpendicularly through the dorsal surface of the skull at the caudal aspect of the frontoparietal scale to penetrate at least 140 mm into the adult skull to ensure severing of the spinal cord. Each device had an approach to positioning and securing the probe with a guide placed above the frontoparietal scale, which was either a head brace, such as used in Device 1, or a head plate and strap, such as used in Device 4. Each device had a 9 mm stainless steel probe sharpened to a rounded or chisel point at one end and a strike plate for the sledgehammer welded on the other end. Probe deployment was made by a single blow from a 5 kg sledgehammer “dropped” with force directly vertically from approximately 50 cm above the strike plate.

Device 1 was a frame prototype of a proposed enclosed box that would contain the turtle’s head and discourage movement. There was a high correlation between head width and length. Therefore, by designing the head brace to expand forward when a wider head was inserted, the turtle head could be reliably inserted to accurately line up the caudal edge of the frontoparietal scale when the head is fully inserted.

Devices 2 and 3 created a small head plate and probe guide that could be affixed to the head of the turtle immediately above the frontoparietal plate. A strap affixed the device in place.

Device 4 refined the previous devices, following trials with each device, by shortening the probe and curving the head plate to better fit the skull.

These devices were used on all of the animals included within this study.

Figure 1: Device evolution throughout the project. All conform to the same mechanism of action.

Device 1



Device 2



Device 3



Device 4



Carcasses (probe, broom and stone)

Probe: The device was tested on 11 green marine turtles carcasses ranging in size from small juveniles through to large adults. The harness device was tested on carcasses sourced from Australian Wildlife Hospital, Queensland Parks and Wildlife Services, Underwater World (Merlin) and TSRA. All turtles were euthanased based on independent grave diagnoses or as part of a normal subsistence harvest. No capture or restraint of these animals was required.

Each turtle had one of the devices described above deployed using a 9 mm probe. Each deployment was filmed and photos taken for assessment by the governing AEC committee and research analyses. The probe was carefully removed to ensure no further damage to the brain. A standard necropsy was performed.

Although not part of this project's objectives, broomstick and stone methods were examined for mechanism of action as requested by Traditional Owners.

Broomstick: For five carcasses, the broomstick method was replicated by inserting a 3 mm wide 240 mm long steel tent peg through the nares and tracking the peg as close to the centre of the vomer as possible. Insertion was assisted by light tapping with a hammer. The paths of the probe were determined by tracking its entry and exit using flexible tubes; or by leaving the probe in place to soft tissue and bone dissect down to the probe.

Photos were taken of the path for assessment by the governing AEC committee and research analyses. A standard necropsy was performed.

Stone: For four carcasses, the stone method was replicated by delivering a sharp blow with a 1.8kg hammer with reasonable force to the rostral most aspect of the rostrum midline between the nasal nares and to the top of the head along the midline at the frontoparietal scale.

Photos were taken of the external damage for assessment by the governing AEC committee and research analyses. A standard necropsy was performed.

Anaesthetised live turtles

For 5 turtles that were independently deemed to be candidates for euthanasia by the rehabilitation facility they were admitted to, the device and probe was deployed on them while under a full plain of anaesthesia. Anaesthesia was achieved by administering Alfaxalone anaesthetic solution at 10 mg/kg intravenously (Scheelings, 2013) via the cervical dorsal fossa. The turtle was then placed in lateral recumbency and monitored for effect of anaesthesia (loss of response to deep pain stimuli, loss of jaw tone and palpebral reflex, but maintenance of spontaneous ventilation and cardiac function). Time to reach a full plain of anaesthesia was recorded.

Achievement of death was measured by a veterinarian using standard assessment of loss of palpebral reflex, menace response, jaw tone, spontaneous respiration, and cardiac activity. In addition, a nerve conduction study was undertaken on one turtle by placing an electrical conductivity meter probe in the optic nerve by surgical implantation behind the eye and another probe placed in the spinal cord at the C3 level through a dorsal midline incision made using a 22 scalpel blade and measured for electrical activity using an ECG.

For each animal, the brain was collected, preserved and assessed as described above.

If the device did not achieve euthanasia with one percussive blow or any of the above indicators of death were not met, a euthanasia solution (sodium pentobarbitone @ >100 mg/kg) was administered intravenously via the cervical dorsal fossa into the jugular vein (Flint et al., 2010).

Field captured live turtles

For two live healthy turtles caught for consumption, the device was demonstrated to hunters by community members employed by TSRA while the PI was present. The harness (Device #4) was fitted and deployed as described above. The euthanasia was recorded. The opportunity was given for community members to ask questions on the device and give opinions on design and the project.

Achievement of death was measured by a veterinarian using standard assessment of loss of palpebral reflex, menace response, jaw tone, spontaneous respiration, and cardiac activity. The animals were butchered for consumption.

Confirmation of method success

Each turtle (head and body when available) had a comprehensive necropsy conducted (Flint et al., 2009). Modification on this protocol was the head was removed at the C2-C3 intervertebral space and the brain dissected out of the cranial case via a midline longitudinal incision through the skull and first two cervical vertebrae, creating two hemispheres including the spinal cord through to the forebrain. The brain was carefully dissected out for preservation in 10% NB formalin solution for a minimum of 3 days (or until the tissue floated) to ensure complete preservation. After this time the whole brain was transversely serially dissected and stained with haemotoxylin and eosin. Area of remnant hindbrain (determined by anatomic location) was estimated as a proportion of hindbrain present by comparison with known hindbrain area for similar sized green marine turtles. Ablation of the majority of the hindbrain including proportion of severed spinal cord was considered successful in achieving euthanasia by replicating pithing and decapitation in a single function. Pithing and decapitation causing destruction of the brain and spinal cord is recommended by the AVMA Guidelines on Euthanasia (Leary et al., 2013) (http://www.aphis.usda.gov/animal_welfare/downloads/reports_out/euthanasia.pdf) as an acceptable combination method for the euthanasia of reptiles.

Effectiveness of the device, broom stick and stone methods were determined.

Community feedback

After demonstrations on the live turtles to each community, at least one device was left with the Community Ranger/TSRA representative/ Community Elder to lend to hunters to trial for approximately 6 months. After this time, TSRA officers contacted each device controller and asked for the feedback of the community. Summaries were dictated to the TSRA who provided these texts to the PI for assessment. Findings are presented as unedited paraphrasing. Conclusions based on these opinions were weighted and drawn.

Permitting considerations

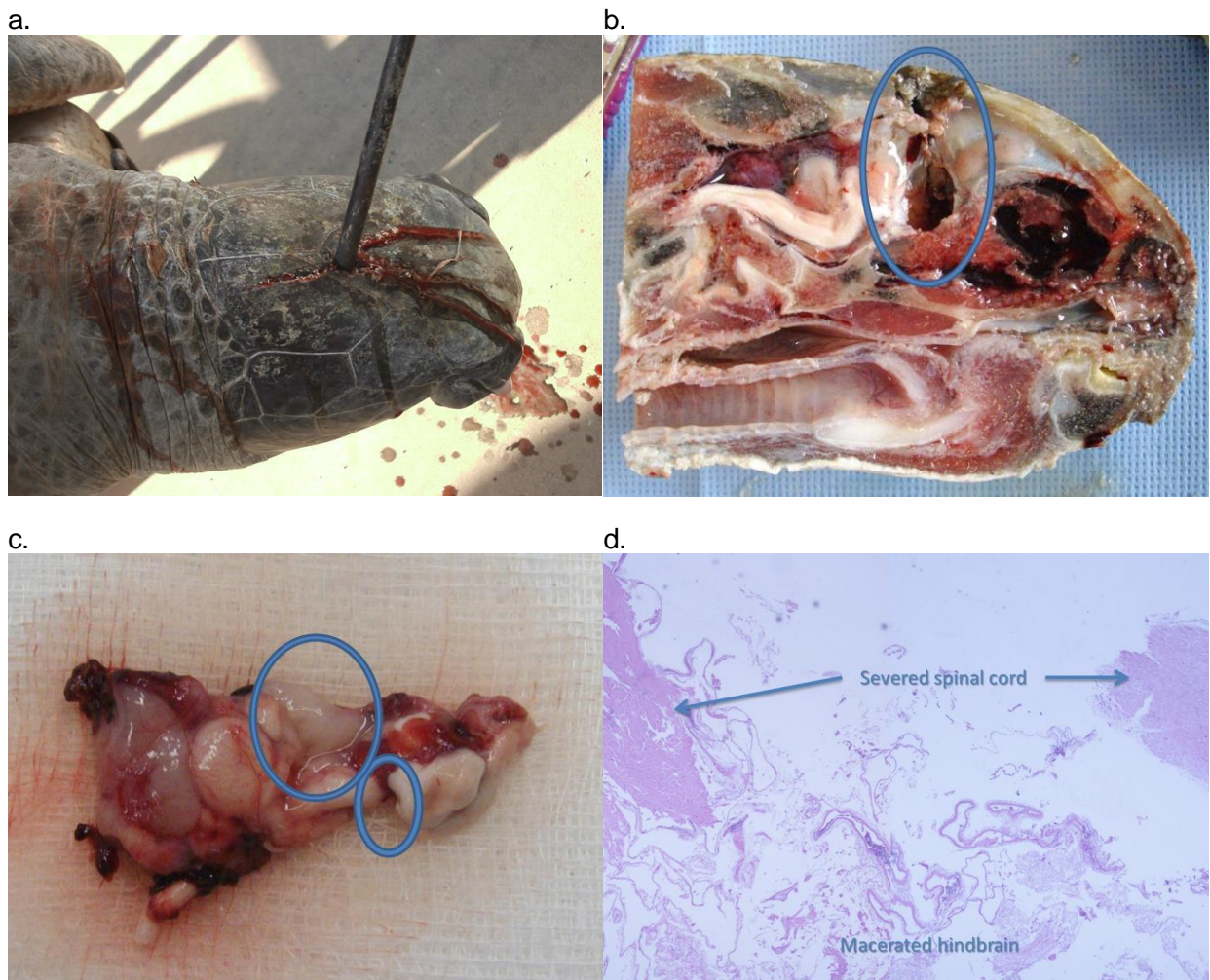
Before the start of research, human and animal ethics as well as state permits to handle marine turtles was obtained to enable collection of the carcasses, live turtles from rehabilitation centres, and to interact with Traditional Owners within the Torres Strait Island Communities.

RESULTS

Carcasses (probe, broom and stone)

For the 11 carcasses on which the probe was deployed, this method was considered successful for nine carcasses (81%, 9/11; 95% CI 48.2- 97.7; Figure 2). For the two failures, in both cases the probe did not penetrate the cranial case. Success was defined as at least partially severing the spinal cord and ablating more than 50% of the hind brain.

Figure 2: Typical (a) presentation for correct penetration of the device through the skull at the caudal aspect of the frontoparietal scale; (b) longitudinal section showing passage of probe (encircled) with severed spinal cord and ablated midbrain with disruption of the hindbrain; (c) gross appearance of a brain that has successfully had the device deployed where the hind brain is ablated (large circle) and spinal cord (small circle) is severed; and (d) the resultant histology showing separation of the spinal cord (arrows) and the disrupted architecture of the hindbrain.



For the five carcasses which the broom method was trialled, the 3 mm probe did not penetrate the cribriform plate. It deflected against the bone and exited via the path of least resistance which was the ocular orbit on at least three occasions (Table 2).

For the four carcasses that were examined using the stone method, compression fractures were noted when blows were delivered on the rostrum and the top of the skull across the parietal scale. Under no conditions was there penetration of the skull. Histologically, damage to the brain was restricted to localised haemorrhage (Table 2).

Broom and stone methods showed no evidence of brain integrity disruption. There may well be transient concussive injury that causes loss of consciousness in a live turtle while exsanguination is performed, but it appears ineffective as a method of euthanasia. The merits of it as a concussive agent need to be independently assessed (Table 2).

Table 2: Stage 1 (carcasses) and Stage 2 (live) outcomes for the three methods employed to achieve euthanasia.

Status	Method	<i>n</i>	No. of successes	Success rate (%)
Dead	Probe	11	9	81
	Broom	5	0	0
	Stone	4	0	0
Alive	Probe	7	7	100

Live turtles (probe only)

Only the probe was used on live turtles, for which five were anaesthetised prior to device deployment and two were euthanased by local Indigenous hunters in country while the researcher was present as part of the device trials. In all cases, deployment was successful within 3 minutes with an average of 96.7 seconds from deployment to confirmed death. Death was quicker if the probe was deployed correctly (Table 3). Where gross examination and histology were performed on the brain, findings were consistent with those reported for probe deployment on the carcasses.

Death was confirmed by absence of respiration, deep pain reflex and palpebral reflex. Heart beat was considered a secondary assessment tool.

Table 3: Duration from deployment of device to confirmed death of the turtle in live turtles.

Turtle	Time (s)	Anaesthetised
1	180	Y
2	10	Y
3	180	Y
4	10	Y
5	10	Y
6	107	N
7	180	N

Histology

For the 27 examined turtles, histology was performed on 22 of them (all bar five live turtles- three euthanased through a rehabilitation centre and two from the participating Indigenous communities). In all cases, histology confirmed whether the probe had successfully hit the target tissues and the degree of tissue damage. All hindbrains and spinal cords were at least 50% destroyed in the successfully euthanased turtles.

Community feedback

After the community demonstrations on the live turtles approximately 12 months after the first island visits, the device was left with the community hunters and/or rangers for use within the community over the next 6 months. Feedback was of mixed opinion.

Mabuiag hunters used the device twice. They felt it was not as effective as traditional methods with respect to instant death, the device was hard to fit to the turtle head and it did not accommodate the range of turtle sizes they harvested. More awareness and support to use the device was requested.

Masig hunters used the device. They understood the issues that surround the way marine turtle are being traditionally butchered and were supportive of the Harness Project trials. They expressed design concerns including the number of people required to deploy the device (3 people vs. usual single hunter), probe thickness and sharpness, securing the device to the head, and plate moulding needed adjustment.

Badu hunters used the device at least twice. Like the Masig hunters, they were aware of the negative publicity that surrounded marine turtle hunting and therefore traditional owners/ hunters were willing to support the trials of the Harness Project and work towards making things better for communities. They expressed similar design concerns as the Masig hunters in probe thickness, securing the device to the head, the fact that it did not fit all turtle sizes, and needed 2-3 people to deploy the device.

DISCUSSION

This research program builds on the preliminary study conducted by our colleagues in Hawaii (Work and Balazs, 2013). It met its aim to establish an alternative option for the humane euthanasia of marine turtles for the participating Torres Strait Island Communities. It also met each of its four objectives to: (i) develop a euthanasia harness device for testing; (ii) trial the harness in a step-wise manner on carcasses through to live healthy marine turtles to ensure a robust effective design; (iii) engage the Indigenous Communities in developing and trialling the device through visits and feedback; and (iv) progressively report ongoing and final findings to the TSRA and Project Steering Committee.

Over 3.5 years of testing, we developed a device capable of penetrating the skull using a 9 mm stainless steel probe over the caudal aspect of the frontoparietal scale. When correctly positioned and deployed with sufficient force, the probe is able to pass through the caudal aspect of the brain and effectively ablate the hind brain and sever the spinal cord (Figure 1). This successfully achieved euthanasia via two mechanisms. Ablating the hindbrain is the equivalent of pithing- the destruction of neural tissue rendering the recipient to have no cognitive function or feel pain (Blood and Studdert, 2000). Severing the spinal cord is the nervous equivalent to decapitation. Decapitation is the removal of the head (Blood and Studdert, 2000) whereby the organs are deprived of all involuntary functions, rendering the recipient dead. Pithing and decapitation comply with international standards for humane euthanasia in a large reptile (Leary et al., 2013).

Pithing is not recommended in animals intended for human consumption due to risk of the emboli of specified risk material moving to the lungs or muscles that are eaten (Appelt and Sperry, 2007); however, there is no known specified risk material (e.g. bovine spongiform encephalitis prions in cattle) in a wild caught healthy marine turtle of the Torres Strait.

When deployed on live animals (Table 2), the device was effective in causing euthanasia between 10 seconds and 3 minutes (Table 3). This is within acceptable timeframes identified in slaughter of livestock (Grandin, 1994).

The stone and broomstick methods did not achieve euthanasia through ablation of the hindbrain and severing of the spinal cord as outlined as requirements for this study (Table 2). These methods have been long used by hunters within the Torres Strait communities and are reported to be effective methods of euthanasia. The low sample sizes used to test these methods in this study do not support this theory. However, these methods may have merit as an important part of the Traditional hunting practice. While they do not appear to cause death in the marine turtle, by shocking the cranial and peripheral nerves associated with the head, they may both cause sensory overload to the brain and result in loss of consciousness allowing for euthanasia to be humanely performed by exsanguination. In this respect, these methods are a variance of the

standard electrical stunning that results in instantaneous loss of consciousness and tonic-clonic muscular movement. These practices are used in a range of species of different sizes in abattoirs throughout the world (Grandin, 1994).

Limitations to this device were noted during the carcass and live turtle phases. For successful deployment of the device, it needs to be positioned correctly, both over the right place on the skull but also deployed at the right angle (perpendicular to the top of the skull in both planes). To maintain this position, time is required to fit the device correctly. When this was not achieved, the probe missed the hindbrain and spinal cord (Table 2). While this was easily achieved under laboratory conditions, it was more of a challenge in healthy, active animals.

In this study, histology was limited to confirming that target structures had been destroyed and the extent of destruction (Figure 2b). From the live animals that were successfully euthanized while under anaesthesia, it was shown that death occurred even if only 50% of the brain and spinal cord was disrupted. Minimal tissue destruction requirements were not determined.

After 3 years of support, the communities still expressed concerns about the need and design of the device including usability in country. However, they expressed a willingness to continue to trial and refine the device.

An agreeable final device design that can be used by a single hunter to euthanase a marine turtle in a quick and effective manner will require further modifications, but this seems feasible on the results and support to date.

CONCLUSION

Based on these findings, we conclude:

- The project was a success and delivered on all planned objectives;
- The developed device severs the spinal cord and ablates the hindbrain in a manner that is in accordance with recommendations by the AVMA Guidelines on euthanasia for reptiles and would achieve the requirements of the *Animal Care and Protection Act 2001* to cause as little pain as is reasonable;
- Indigenous hunters and Community members are supportive of the device and project objectives and are willing to trial future versions and provide feedback; if
- Further modifications are made to the device to improve ease of use including single person deployment.

Additional investigation in response to requests by Indigenous hunters indicated:

- The current traditional method of shocking (stone) does not kill the turtle, but may be similar to electro-stunning methods causing sensory overload used in abattoirs around the world.

RECOMMENDATIONS

There is no governmental requirement to currently investigate traditional hunting methods. The study we have undertaken has shown the proposed device can work and may be of interest to Indigenous hunters with further modification for ease of use. As such, we recommend this project be concluded at this stage with the potential to re-examine device modifications and community roll out as part of TSRA's commitment to continue to build on the outcomes of this project through working with communities and stakeholders in collaboration with other on-going projects.

We based our recommendation weighing the following salient *pro et contra* statements.

Continuing Device Development Pros:

- Severs the spinal cord and ablates the hindbrain in accordance with current AVMA Guidelines on euthanasia for reptiles and would achieve the requirements of the *Animal Care and Protection Act 2001* to cause as little pain as is reasonable;
- Hunters and community are supportive of the device and project objectives and are willing to trial future versions and provide feedback.

Continuing Device Development Cons:

- There is no legislative requirement for hunters to use the device;
- Hunters want further modifications to the device to improve ease of use (see below);
- Hunters would prefer to use the traditional method because it is what they have been taught and practised for generations. For them, these methods are easier to use and one person can complete the task;
- Number and availability of devices to hunters is difficult when needed and they come at a cost;

Next steps:

If there is a future need to refine the final device developed in this project, it is recommended the approach to euthanasing the turtle remains the same (ablation of the hindbrain and severing of the spinal cord using an 8-10 mm sharpened probe). However, the following modifications may help improve the usage and uptake of the device.

1. The device may require removal of the plate for easier use,

2. A smaller hammer for sharp blows to insert the hand held probe,
3. Determine landmarks that may be used to gain probe entry from the ventral side of the head so the turtle can be placed on its shell during deployment and be dispatched by one operator, and
4. Incorporation of the device into other community infrastructure such as hunting stations.

REFERENCES

- Appelt, M., Sperry, J., 2007. Stunning and killing cattle humanely and reliably in emergency situations — A comparison between a stunning-only and a stunning and pithing protocol. Canadian Veterinary Journal 48, 529-534.
- Blood, D.C., Studdert, V.P., 2000. Saunders Comprehensive Veterinary Dictionary 2nd Edition. W.B. Saunders, Bath.
- Flint, M., Morton, J.M., Limpus, C.J., Patterson-Kane, J.C., Murray, P.J., Mills, P.C., 2010. Development and application of biochemical and haematological reference intervals to identify unhealthy green sea turtles (*Chelonia mydas*). The Veterinary Journal 185, 299-304.
- Flint, M., Patterson-Kane, J.C., Limpus, C.J., Work, T.M., Blair, D., Mills, P.C., 2009. Post mortem diagnostic investigation of disease in free-ranging marine turtle populations: a review of common pathological findings and protocols. Journal of Veterinary Diagnostic Investigation 21, 733-759.
- Grandin, T., 1994. Euthanasia and slaughter of livestock. Journal American Veterinary Medical Association 204, 1354-1360.
- Leary, S., Underwood, W., Anthony, R., Cartner, S., Corey, D., Grandin, T., Greenacre, C., Gwaltney-Brant, S., McCrackin, M.A., Meyer, R., Miller, D., Shearer, J., Yanong, R., 2013. AVMA Guidelines for the Euthanasia of Animals: 2013 Edition. American Veterinary Medical Association, Schaumburg.
- Scheelings, T.F., 2013. Use of intravenous and intramuscular Alfaxalone in Macquarie River Turtles (*Emydura macquarii*). Journal of Herpetological Medicine and Surgery: 23, 91-94.
- Work, T.M., Balazs, G.H., 2013. A simple humane method to euthanize a sea turtle. Marine Turtle Newsletter 136, 5-6.

